

A

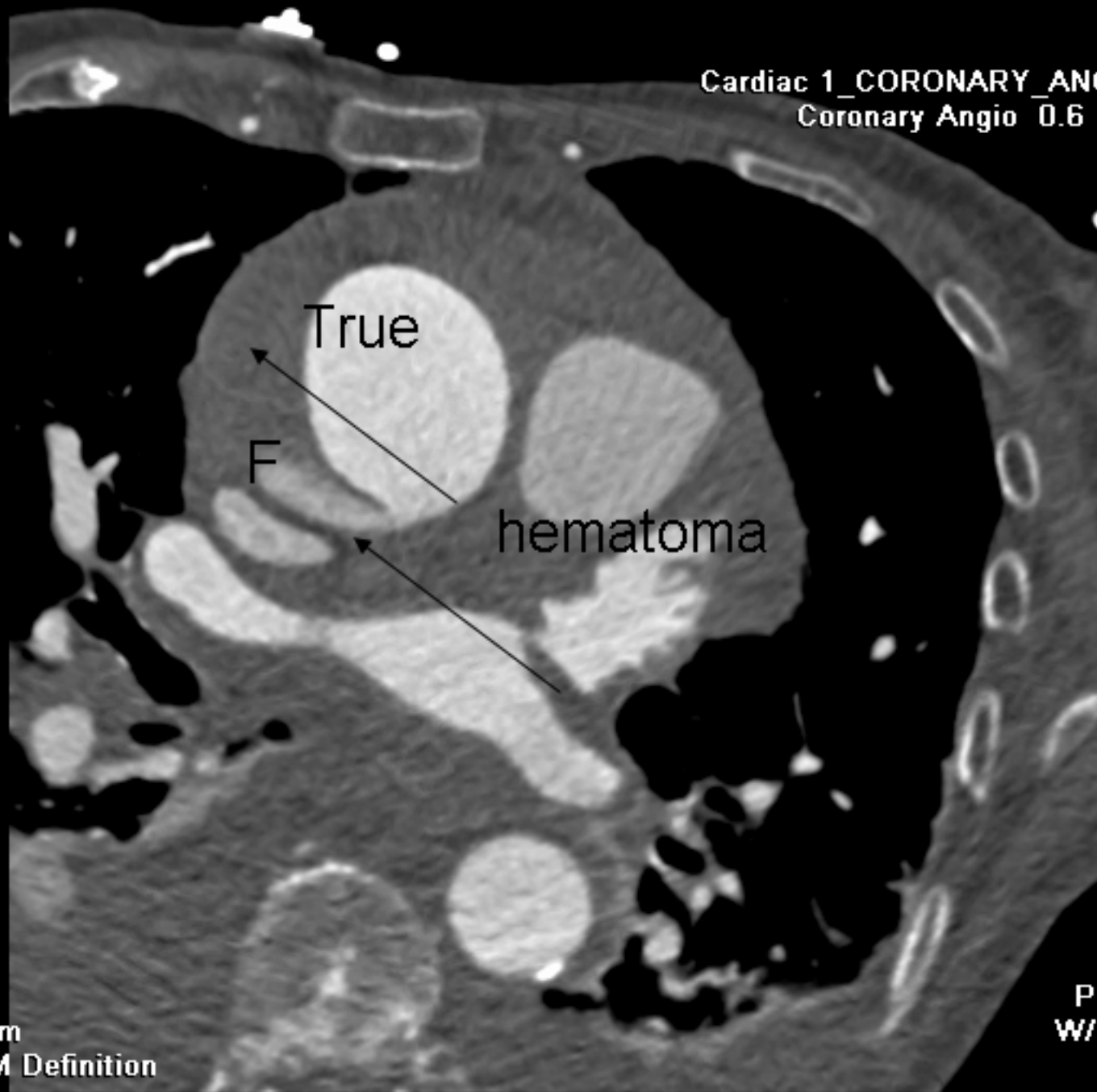
Cedars Sinai Medical Center

CT

Cardiac 1_CORONARY_ANGIO (Adult)

Coronary Angio 0.6 B26f 70%

R



L

2 cm

kVP:120
mA:672
msec:330
mAs:221
Thk:0.6 mm
SOMATOM Definition

Vitrea®
Phase %070
W/L:1000/200
Oblique

P